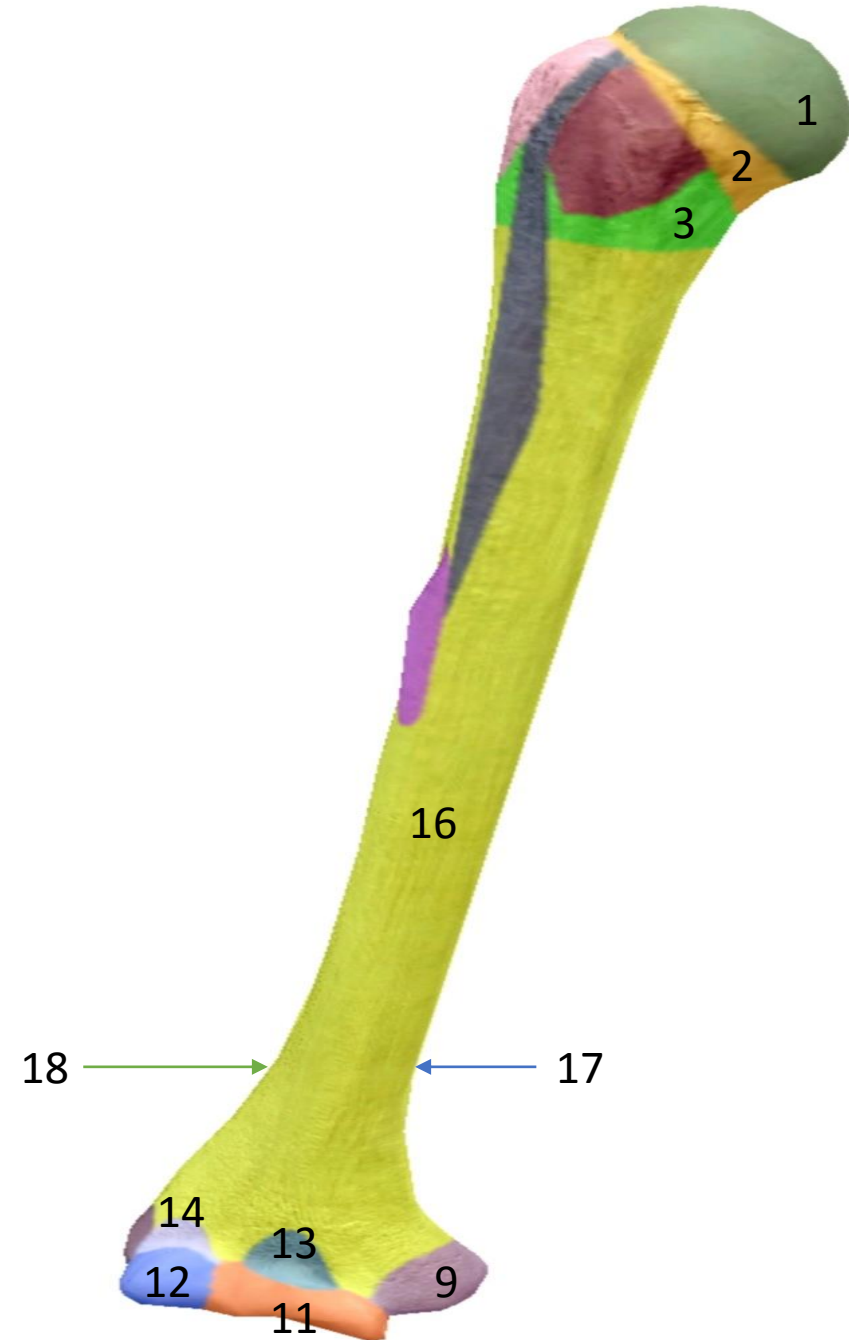



Identify Structures

- 1- Head
- 2- Anatomical neck
- 3- Surgical neck
- 9- Medial epicondyle
- 11- Trochlea
- 12- Capitulum
- 13- Coronoid fossa
- 14- Radial fossa
- 16- Shaft
- 17- Medial supracondylar ridge
- 18- Lateral supracondylar ridge



Identify Structures

- 4- Lesser tubercle
- 5- Greater tubercle
- 6- Intertubercular (BICIPITAL) groove
- 7- Deltoid tuberosity
- 10- Lateral epicondyle



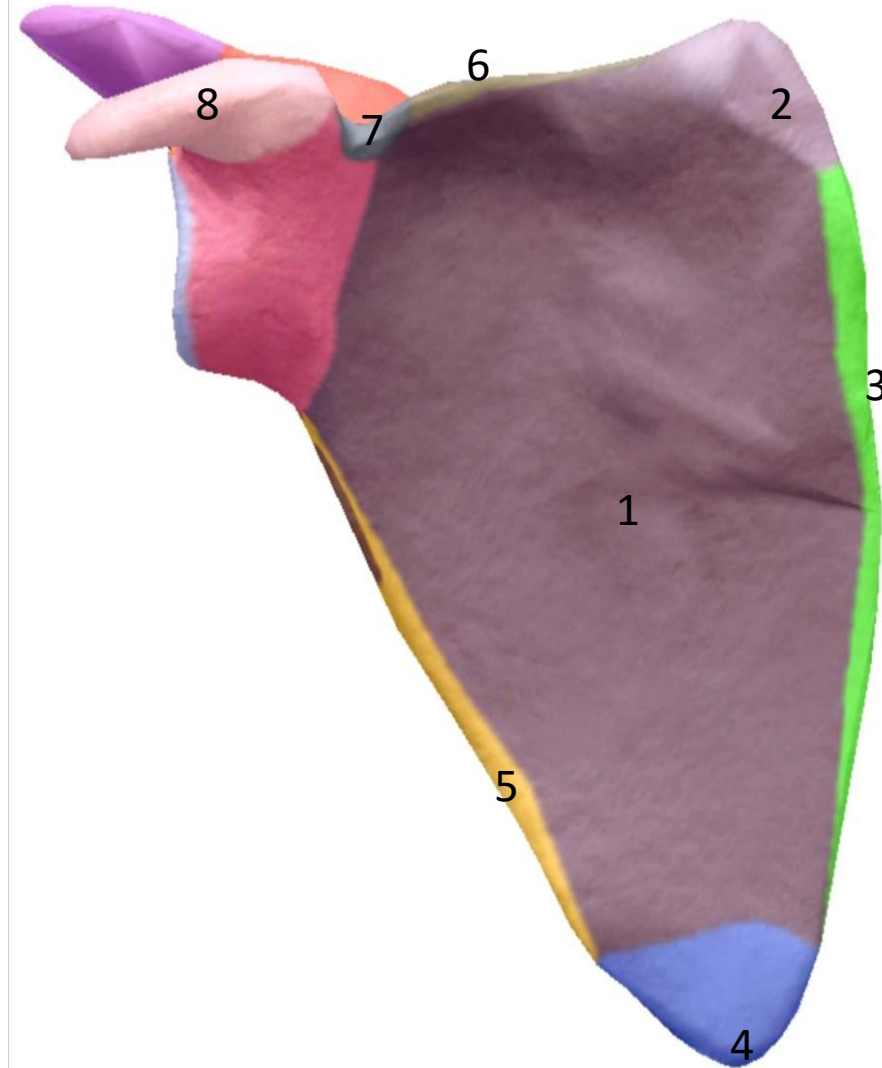
Identify Structures

- 8- Radial groove
- 15- Olecranon fossa



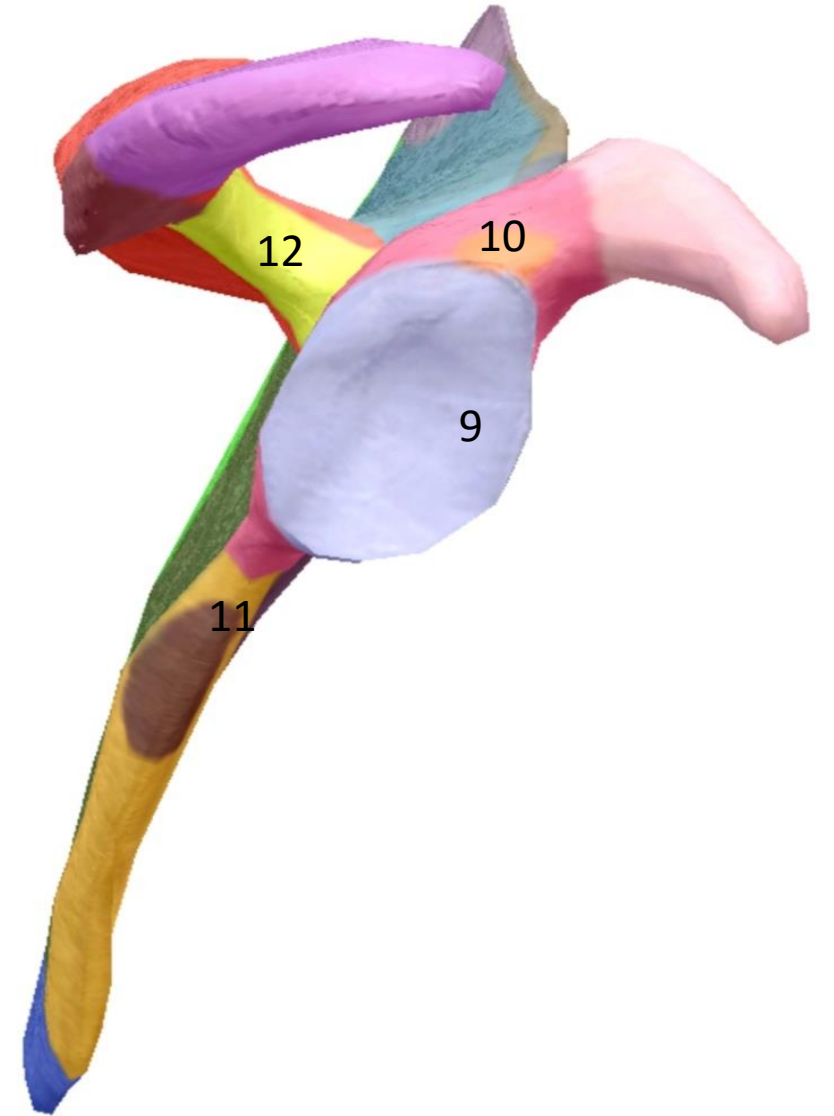
Identify Structures

- 1- Subscapular fossa
- 2- Medial angle
- 3- Medial border
- 4- Inferior angle
- 5- Lateral border
- 6- Superior border
- 7- Suprascapular notch
- 8- Coracoid process



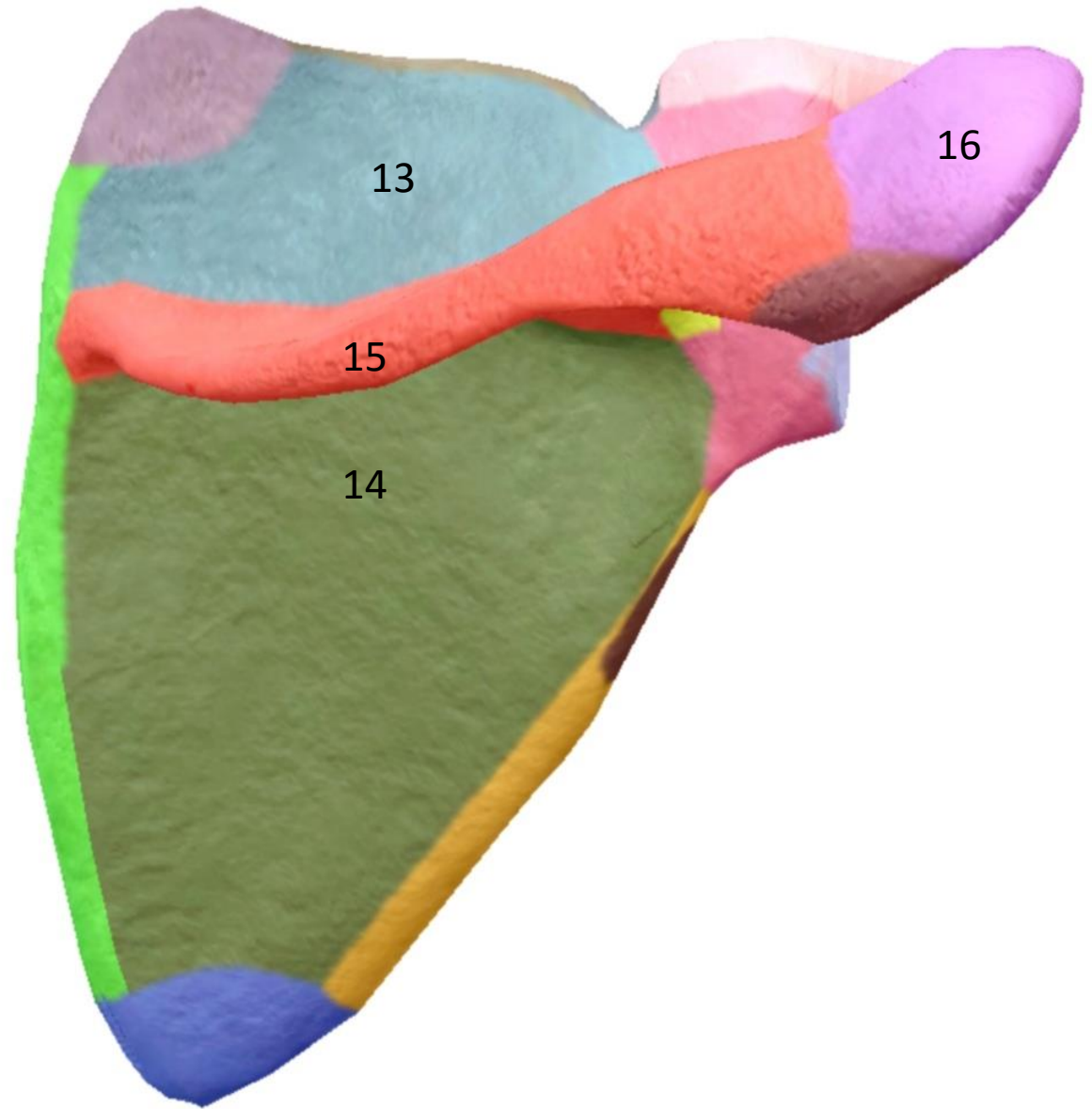
Identify Structures

- 9- glenoid cavity
- 10- Supraglenoid tubercle
- 11- Infraglenoid tubercle
- 12- Grater scapular notch



Identify Structures

- 13- Supraspinous fossa
- 14- Infraspinous fossa
- 15- Spine of scapula (Spinous process)
- 16- Acromion



Right OR Left

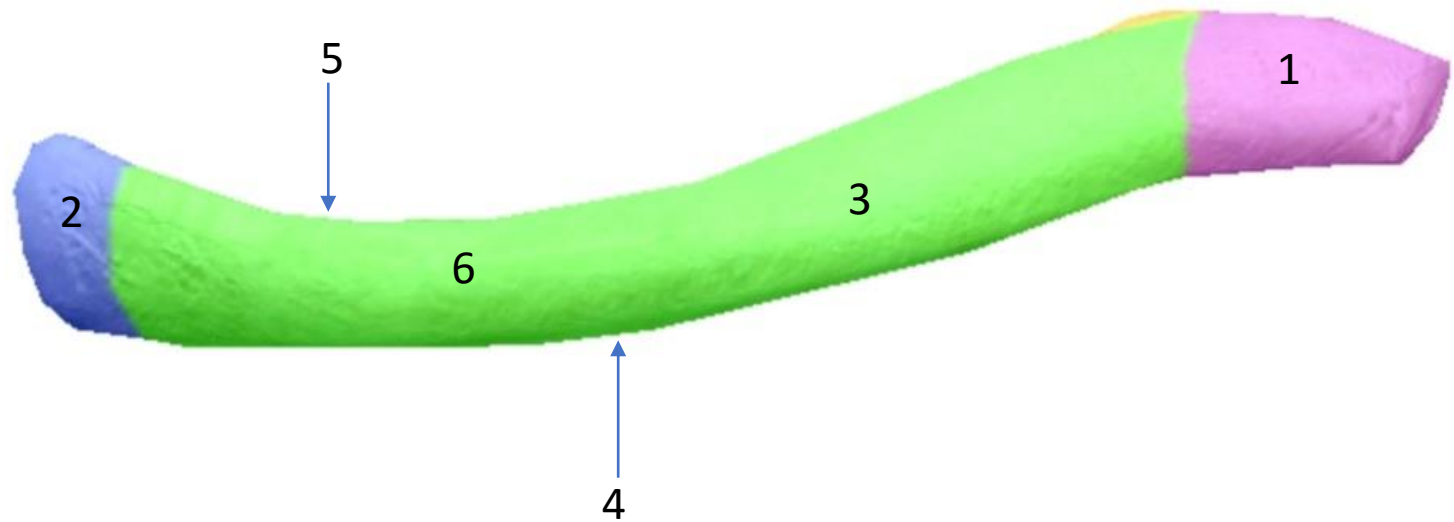


Right OR Left




Identify Structures

- 1- Lateral end
(Acromion end)
- 2- Medial end
(Sternal end)
- 3- Shaft
- 4- Anterior border
- 5- Posterior border
- 6- Superior surface



Identify Structure

7- Inferior surface



Right OR Left



Right OR Left

